

# Comprehensive Lower Eyelid Rejuvenation

Guy G. Massry, M.D.<sup>1</sup>

## ABSTRACT

Historically, lower eyelid blepharoplasty has been a challenging surgery fraught with many potential complications, ranging from ocular irritation to full-blown lower eyelid malposition and a poor cosmetic outcome. The prevention of these complications requires a detailed knowledge of lower eyelid anatomy and a focused examination of the factors that may predispose to poor outcome. A thorough preoperative evaluation of lower eyelid skin, muscle, tone, laxity, fat prominence, tear trough deformity, and eyelid vector are critical for surgical planning. When these factors are analyzed appropriately, a natural and aesthetically pleasing outcome is more likely to occur. I have found that performing lower eyelid blepharoplasty in a bilamellar fashion (transconjunctivally to address fat prominence and transcutaneously for skin excision only), along with integrating contemporary concepts of volume preservation/augmentation, canthal eyelid support, and eyelid vector analysis, has been an integral part of successful surgery. In addition, this approach has significantly increased my confidence in attaining more consistent and reproducible results.

**KEYWORDS:** Transconjunctival lower lid blepharoplasty, tear trough deformity, canthopexy, eyelid fat grafting, eyelid vector

Attaining a successful aesthetic outcome to lower lid blepharoplasty can be quite challenging. The lower lid is a very temperamental facial structure whose surgery is fraught with both functional and aesthetic complications such as eyelid malposition, dry eye, ocular irritation, blurred vision, tearing, and poor aesthetic outcome.<sup>1-3</sup>

The traditional (transcutaneous) approach to lower eyelid blepharoplasty involves excision of varied amounts of skin, muscle, and fat. This subtractive form of surgery is typically performed through a cutaneous, subciliary incision<sup>4</sup> with violation of several tissue planes (orbicularis muscle and orbital septum) that potentially promote the postoperative complications mentioned above.<sup>5</sup>

The addition of adjunctive procedures that support the eyelid through lateral tightening advanced our ability to prevent poor surgical outcomes.<sup>4,6,7</sup> Despite these lateral tightening procedures, the incidence of a

surgical look (rounded, hollow, retracted eyelid) with traditional lower lid blepharoplasty remains unacceptably high.<sup>8</sup>

The reintroduction of transconjunctival surgery in 1989<sup>9</sup> significantly reduced the incidence of eyelid malposition in lower lid blepharoplasty.<sup>9,10</sup> Subsequent advances in our understanding of the previously underappreciated conceptual and anatomic factors that lead to a successful lower lid blepharoplasty enable us to prevent many blepharoplasty problems and complications.

In this article, I will outline the approach that I have developed to lower lid blepharoplasty over the past decade. The foundation of this thought process is a bilamellar surgery that addresses lower eyelid fat through a transconjunctival incision and excess skin through a subciliary skin flap only. This approach incorporates preservation of the integrity of the orbital septum and orbicularis muscle, in addition to adjunctive procedures

<sup>1</sup>Ophthalmic Plastic and Reconstructive Surgery, Spalding Drive Cosmetic Surgery and Dermatology, Beverly Hills, California.

Address for correspondence and reprint requests: Guy G. Massry, M.D., 120 S. Spalding Drive, No. 315, Beverly Hills, CA 90212 (e-mail: Massrymd@aol.com).

Blepharoplasty and Brow Lifting; Guest Editor, Gregory S. Keller,

M.D., F.A.C.S.

Facial Plast Surg 2010;26:209-221. Copyright © 2010 by Thieme Medical Publishers, Inc., 333 Seventh Avenue, New York, NY 10001, USA. Tel: +1(212) 584-4662.

DOI: <http://dx.doi.org/10.1055/s-0030-1254331>.

ISSN 0736-6825.

such as lateral canthal tightening, volume preservation<sup>11-14</sup> and augmentation,<sup>15,16</sup> and more comprehensive eyelid support.

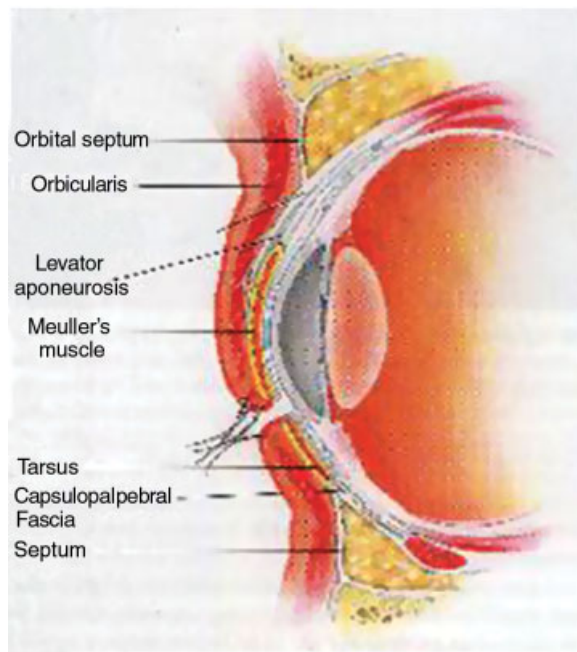
### LOWER EYELID ANATOMY (FIG. 1)

The lower lid can be separated into various lamella or layers. In the first 5 mm of the lid, starting with the lashes and preceding inferiorly, the skin and pretarsal orbicularis muscle form the anterior lamella. The posterior lamella is composed of the tarsus and conjunctiva.

Below this level the lid becomes more complex. The anterior lamella is still formed by the skin and orbicularis muscle.

A third, or middle, lamella develops, which consists of a connective tissue structure called the orbital septum. The orbital septum originates at a condensation of periosteum at the inferior orbital rim called the arcus marginalis. It inserts onto the inferior edge of the tarsal plate. It is loosely adherent to the preseptal orbicularis muscle on its anterior surface.

Posterior to the septum is the lower eyelid fat, which is addressed during surgery. Posterior to the fat are the lower eyelid retractors, also called the *capsulopalpebral fascia*. This fascial/muscular layer originates from the inferior rectus muscle and fuses with the orbital septum 3 to 5 mm below the tarsus. This common fusion point is important surgically, as to enter the fat compartment transconjunctivally, the incision must be below the



**Figure 1** A sagittal section. (From Dresner SC, Marshak H. Transjunctival lower blepharoplasty. In Azizzadeh B, Murphy M, Johnson CM, eds. *Master Techniques in Facial Rejuvenation*. Philadelphia: WB Saunders; 2007:90. Reprinted with permission.)

landmark. The conjunctiva lies on the internal surface of the capsulopalpebral fascia and is very adherent to it, with the two layers forming the posterior lamella (below the tarsus).

There are three fat compartments in the lower lid: nasal, central, and temporal. The nasal and central compartments are separated by the inferior oblique muscle, whereas the central and temporal compartments are divided by the inferior arcuate ligament.

### WHY LOWER EYELID SURGERY IS A PROBLEM

The lower lid is an anti-gravitational structure not best suited for aesthetic surgical intervention. To appropriately perform lower eyelid blepharoplasty, the surgeon must address excess or damaged skin, redundant and/or lax muscle, displaced fat, volume changes, eyelid laxity, involutional changes, and anatomic variations, when all support (including gravity) for correcting these deficiencies is against the surgeon. This is clearly not an easy task, and the reason that surgeons have found lower lid blepharoplasty to be such a humbling surgical experience. How then, can this surgery be performed in the most safe and effective manner? To answer this, it is imperative to have a contemporary understanding of the factors which must be addressed, and the concepts which must be adhered to, in order to promote the best functional and aesthetic result.

The position of the lower lid is maintained by a delicate balance of factors which support or act against it. In the normal setting, anatomic factors which support lower lid position include the following:

1. Tendons: The medial and lateral canthal tendons, which act as a sling, maintaining lower lid height and keeping the lower lid abutted against the undersurface of the globe.
2. Ligaments: There are retaining ligaments that fixate the eyelid and cheek soft tissue to the bony facial skeleton.
3. Muscle: The orbicularis muscle, which tonically elevates the lid with its sphincter action.
4. Volume: Both soft tissue (fat) and hard tissue (bone) promote stabilization of facial structures including the lower eyelid.

The factors that act against the lower lid (depress it) include:

1. The lower lid retractors: Like the orbicularis muscle, they are in a tonic state of activity.
2. Normal involutional changes: With age, canthal tendon and ligamentous laxity, loss of soft tissue and bony volume, and reduced muscular support all act to allow the lid to fall.

3. Gravity: As lid support decreases with age and gravity is constant, the equilibrium shifts to retraction.

Clearly, it is easy to see why lower lid blepharoplasty is such a difficult surgery to “get right.” However, there are things we can do to promote outcome. First, I have abandoned transcutaneous surgery altogether.<sup>17</sup> It is known that with this route of surgery, the incidence of lower lid malposition is high, and I believe that almost all these patients followed over time look operated on. Also, I re-create lower lid support with some form of canthal suspension and add volume preservation and/or augmentation when necessary.

### PREOPERATIVE EVALUATION

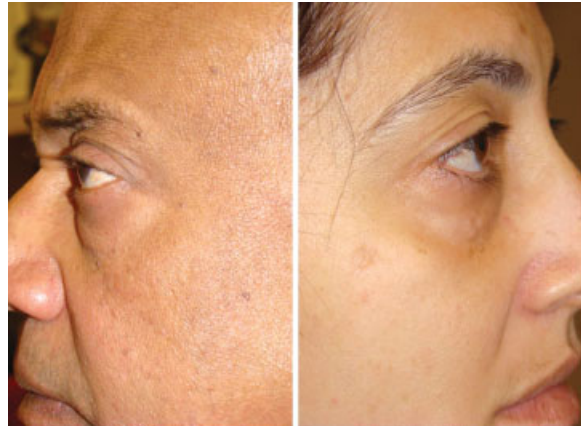As with all procedures, the key to surgical success has more to do with the plan we develop preoperatively than with what we do during surgery. This is especially true with lower lid blepharoplasty, as the room for error is low. I have developed a mnemonic that I have found useful in assessing all lower lid blepharoplasty patients. The mnemonic is SMFTV, whose letters stand for each component of the lower lid which I evaluate prior to surgery (skin, muscle, fat, tone, and vector).

In the evaluation of skin, I ask the patient to look up and open the mouth. As this maneuver puts the lower lid on maximal stretch, only the excess skin I can bunch together in this facial position is excised.

I determine tone of the lid by pulling the eyelid inferiorly and seeing how well it snaps back into place. If this is delayed, I tend to suspend the orbicularis muscle intraoperatively (canthopexy). If the lid does not fall back into position at all, I will also tighten the tarsus itself (canthoplasty). In addition, when skin is excised, I almost always perform some form of lateral lid tightening.

The herniation of fat is determined along with the presence of a tear trough deformity. Depending on findings, fat can be excised, repositioned, or a combination of the two. If the volume deficit is greater than the native fat available for preservation, then fat grafting can also be added.

Eyelid vector is a very important surgical concept. When the tip of the cornea (globe prominence) is more anterior than the prominence of the lower lid/suborbital area (cheek), a “negative vector” is present (Fig. 2). A “positive vector” is the opposite situation. When a negative vector is present, the lid must support itself against an upward slope. Special care must be taken when approaching surgery in this scenario as lid tightening can bowstring the globe, and skin excision may lead to a higher incidence of lower lid malposition. In fact, I have found that fat excision (fat reduction) alone in this setting can lead to subtle degrees of lid retraction.



**Figure 2** Both patients shown in the photo demonstrate more prominent globes relative to the lower eyelid and midface. This negative vector creates increase risk of eyelid malposition with lower eyelid surgery.

### SURGERY

#### Transconjunctival Blepharoplasty

In patients who require repositioning or grafting of fat, these areas are demarcated prior to surgery. I find that tear trough effacement with fat has best results when nasal fat is repositioned and the remainder of the tear trough is grafted with fat.

The lower lids are infiltrated transconjunctivally with 2 mL 1% Xylocaine (Lidocaine, Hospira Inc., Lake Forest, IL) with 1:100:000 epinephrine bilaterally. The portion of the tear trough to be repositioned with fat is further infiltrated with the same anesthetic until it is ballooned up with slight tension. The goal in this area is to create hemostasis with both the epinephrine and mechanical (vascular tourniquet) effects.

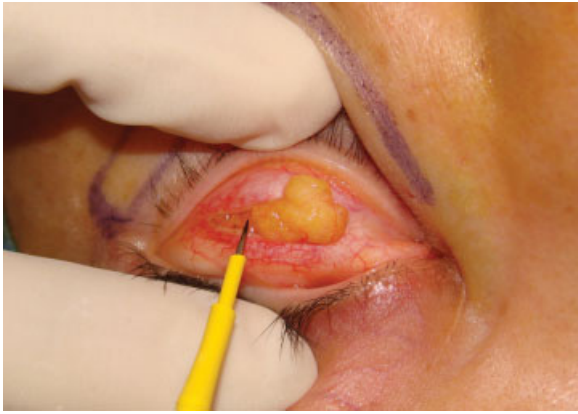The lower lid is displaced inferiorly with the index finger while the globe is retro-placed with the second finger (Fig. 3). This maneuver increases the view of the surgical field and brings the conjunctiva and fat forward for easier access.

An incision is made 4 to 5 mm below the tarsus through the conjunctiva and retractors, which are engaged with a 4-0 silk traction suture and secured to the head drape (Fig. 4). This protects the globe, improves exposure, and acts to somewhat retro-place the eye bringing the fat into the surgical field.

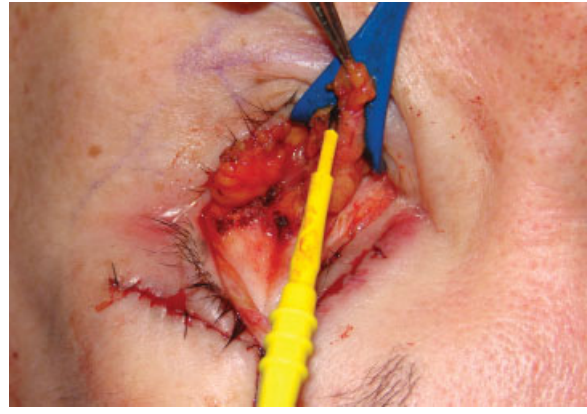
The three fat pads and the inferior oblique muscle are then identified. In cases of fat removal, the fat pads are now excised (Fig. 5). In cases of repositioning, the fat pedicles are prepared. All connective tissue attachments from the fat to the inferior oblique muscle are severed with both blunt and sharp dissection (Fig. 6). I perform these surgical maneuvers with the coagulation mode of the electrocautery unit to prevent bleeding.

I confirm freedom of the fat pads from the muscle by engaging the nasal and central pad with toothed





**Figure 3** Inferior displacement of the lower eyelid with retro-placement of the globe increases surgical exposure of conjunctiva and brings fat forward, simplifying the procedure. Note vertical incision directly enters fat pad.



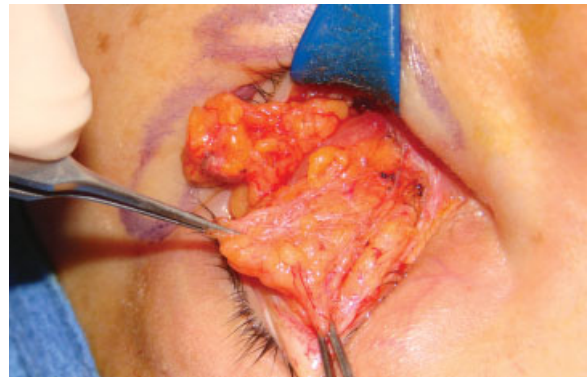
**Figure 5** Excision of fat pad. Cutting fat against an insulated retractor is helpful.

forceps and pulling in opposite directions. I call this the “inverse shoe-shine sign” as it mimics shining a shoe from its undersurface (Fig. 7).

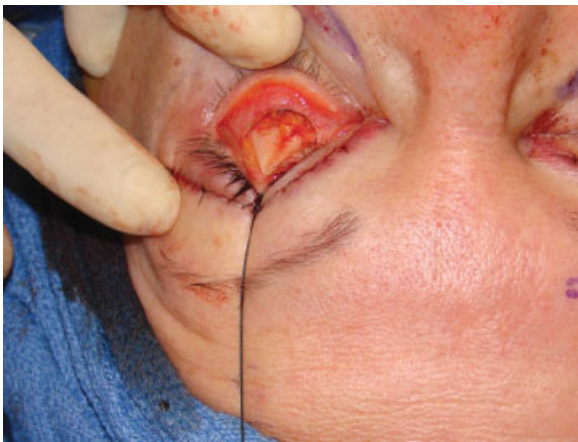The temporal fat pad is cut flush with the orbital rim. An incision is made through the arcus marginalis ~2 mm inferior to the orbital rim, and subperiosteal dissection progresses in a nasal and temporal direction to the infraorbital neurovascular bundle (Fig. 8). As this area tends to bleed, I pack the subperiosteal pockets with cotton soaked in 1:10,000 epinephrine. I proceed to the opposite eye and perform the same surgery to this point. This gives time for hemostasis to take effect.

I then remove the cotton pledgets. I reposition the fat pedicles by passing a 4-0 Prolene suture (Ethicon, San Lorenzo, Puerto Rico) on a long needle (PS-2) through the skin below the demarcation of the tear trough through both ends of the splayed out fat pedicle and then back through the skin (Fig. 9). The suture is tied over a cotton bolster. It is important not to tie the fat down too tightly as this can lead to increased swelling and fat necrosis or too loosely so as not to allow the fat

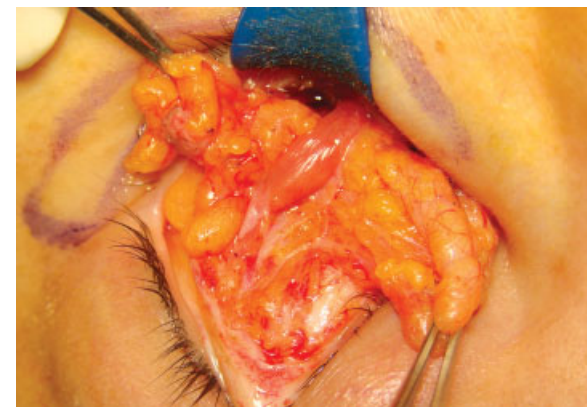pedicle to retract. The goal is to create an implant effect just below the bony rim to fill the trough. I allow the wound to heal by secondary intent without sutures and perform forced ductions to ensure no restriction of globe movement.



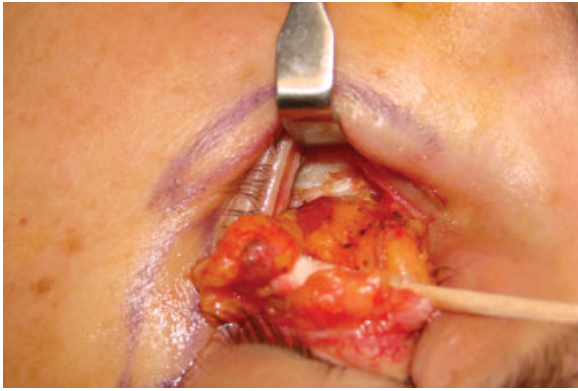
**Figure 6** Creation of fat pedicles. Ensure freedom from inferior oblique muscle, which is present centrally (between fat pads) in the photo.



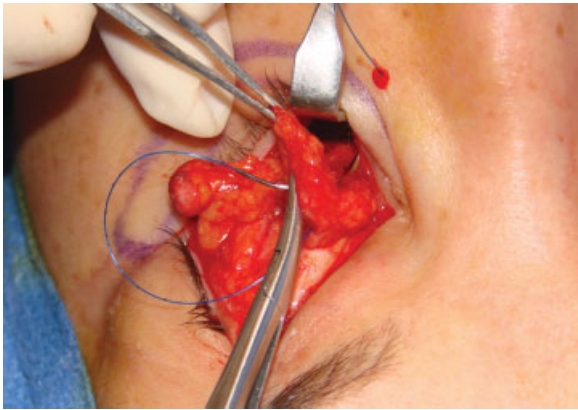
**Figure 4** A traction suture secured to the head drape protects the globe and increases surgical exposure.



**Figure 7** Inverse shoe-shine sign. The nasal and central fat pads move freely under the oblique muscle.



**Figure 8** Note the fat pads, inferior oblique muscle, and subperiosteal dissection starting at the orbital rim.



**Figure 9** Fat pedicle being engaged with Prolene suture for repositioning.

### Canthal Surgery

Various forms of lid tightening through a canthal access point have been described. The majority of these suspend the lid through shortening or tightening the lateral canthal tendon or terminal orbicularis muscle. I group these procedures in the family of canthopexy. They are easier to perform and less time consuming (than canthoplasty), typically do not require much canthal disruption, and are adequate for most aesthetic patients.

The more powerful canthal procedure is a true tarsal suspension (traditional canthoplasty) after disengaging the tarsus from all attachments to the lateral orbital rim (canthotomy with lysis of the inferior crus of the lateral canthal tendon). Except in rare instances (elderly patients), this is not an aesthetic procedure. This “tarsal strip”<sup>18</sup> procedure was described for repair of functional eyelid defects, which require tarsal shortening and canthal reconstruction to achieve success.

Conversely, in aesthetic canthoplasty, a tarsal reattachment through a canthotomy without further manipulation of the tarsus or other attachments of the tarsus to the orbital rim is desired. In this way, there is a reduced chance that the position of the canthus will be altered; a critical concern with this surgery. This is the

most aggressive of the aesthetic lid suspensions that we employ and is used in patients with more significant lower lid laxity.

### Canthopexy

My canthopexy preference is an orbicularis suspension, or muscle strapping, as this both provides support for the lid and recruits more skin for excision when necessary. It is performed as follows. The lower lid is infiltrated transcutaneously with 1 to 2 mL of 1% Xylocaine with 1:100:000 epinephrine. After giving sufficient time for hemostasis and anesthesia to take place, an infraciliary and small canthal incision is made, and a skin flap is raised to the inferior orbital rim. The most temporal fibers of the preseptal orbicularis muscle are identified and engaged with a toothed forceps. The muscle is pulled in a supertemporal direction toward the lateral orbital rim. This gives an idea of how the lid will appear after muscle tightening. It also provides guidance as to how much pull is appropriate. Too much tightening can lead to “bowstringing” the globe even in the absence of a prominent eye. Too little tightening defeats the purpose of the procedure and provides inadequate support for the lid.

The orbicularis muscle can be fixated to periosteum in a variety of ways. These include folding the muscle on itself (imbrication), buttonholing the muscle (bluntly with a hemostat) and securing its free edge, or excising a portion of muscle (shortening it) and suturing its free edge.

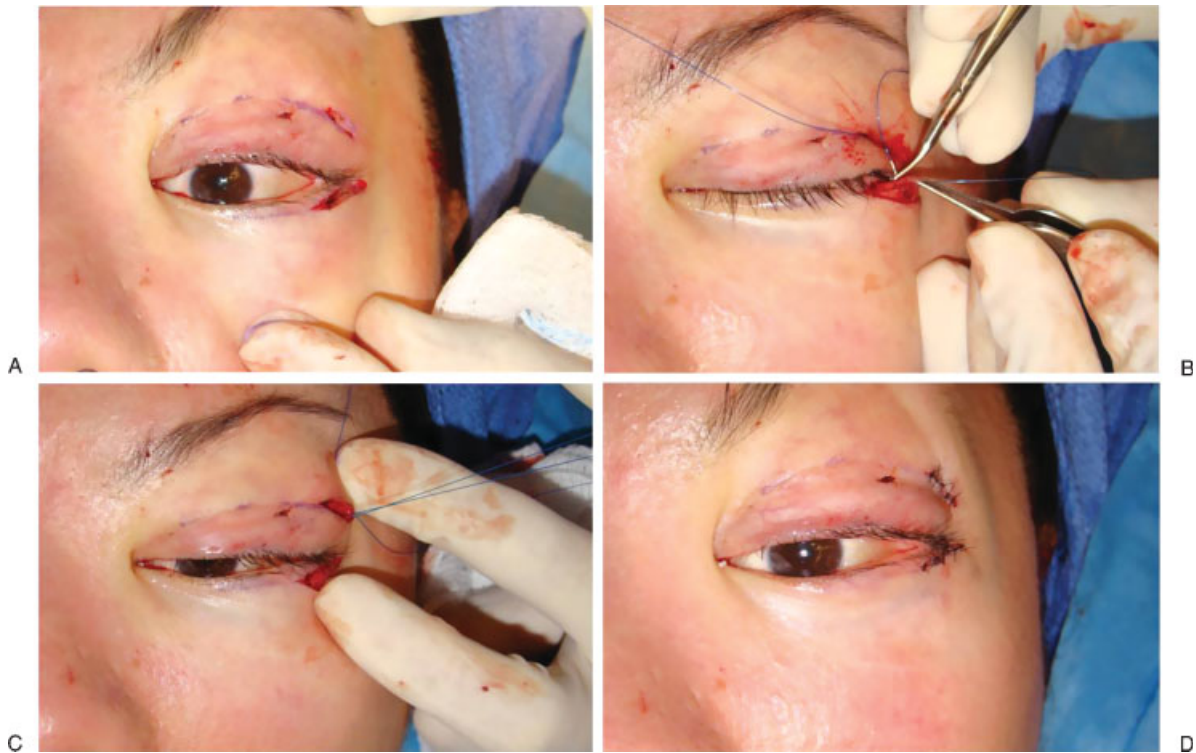
Theoretically, incisions in the muscle can lead to neurapraxia. I have found that, irrespective of type of procedure selected, postoperative muscle weakness is rare. Further, I have found that dividing the muscle (or excising, which I do not prefer) provides longer-lasting results (more tissue trauma probably leads to more scar and subsequent fixation). In addition, imbricating the muscle can lead to fullness (bunching) postoperatively, albeit usually a temporary issue.

The other variable is where to attach the muscle. There are two options. The orbicularis muscle can be attached to the periosteum of the lateral superior orbital rim through a temporal upper blepharoplasty type incision or to the lateral orbital rim periosteum through a canthal incision. I have found both suspension points provide equal support with similar aesthetic outcomes (Fig. 10).

### Canthoplasty

An aesthetic canthoplasty involves a canthotomy without cantholysis (cutting the inferior crus of the lateral canthal tendon). When the inferior crus of the lateral canthal tendon is preserved, I have found a change of the slant of the lid or of the canthus to be rare.





**Figure 10** Orbicularis canthopexy (plication). The terminal orbicularis is (A) exposed, (B) engaged, (C) secured to periosteum through temporal upper lid crease incision. (D) Final wound closure. This patient also underwent internal ptosis repair to the upper lid.

In performing a “canthoplasty,” the terminal tarsus is debrided of epithelium (to prevent inclusion cysts) and is engaged with a 4-0 Vicryl suture (Ethicon, San Lorenzo, Puerto Rico) on a half-circle needle (P-2 or S-2) and re-secured to lateral orbital rim periosteum (Fig. 11). It is critical to reform the canthal angle well without override of upper and lower lid tissue on itself. This is done by passing an upper lid/lower lid suture (6-0 silk or 6-0 chromic gut) from gray line to gray line. When tied, the suture ensures appropriate alignment of the canthus (Fig. 12). I leave this suture long and bury it in the next canthal bite to prevent the suture ends from irritating the eye. The remainder of the canthus is then closed.

### Retractor Lysis

An incision through the lower lid retractors is inherent to transconjunctival lower eyelid blepharoplasty. The incision in the lower lid retractors is beneficial in that it weakens the depression action of this fibromuscular band and shifts the balance of lid position to elevation during the critical postoperative healing period. In those patients who are having no fat manipulation; yet undergo skin excision and/or muscle plication, I have routinely incised the lower lid retractors as in routine transconjunctival blepharoplasty. This provides the

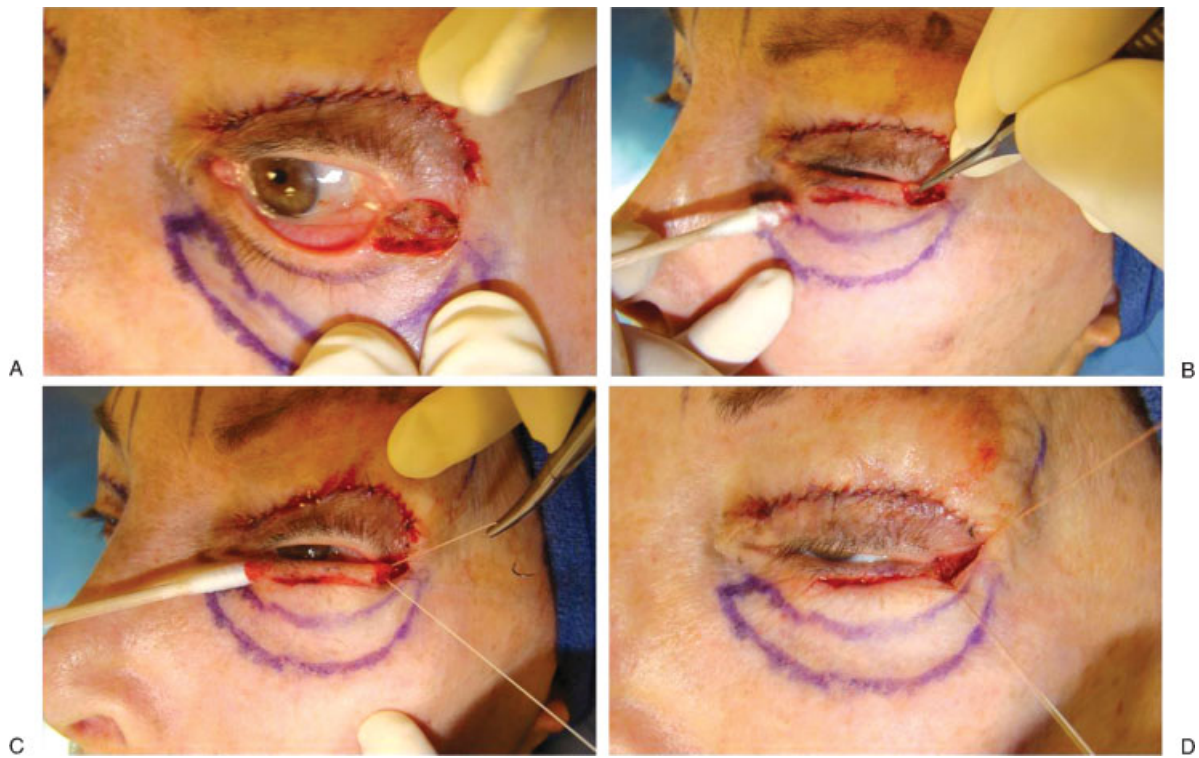
same antidepression effect on the lower lid during healing and acts as an adjunct to prevent lid malposition (Fig. 13).

### Intermarginal Suture

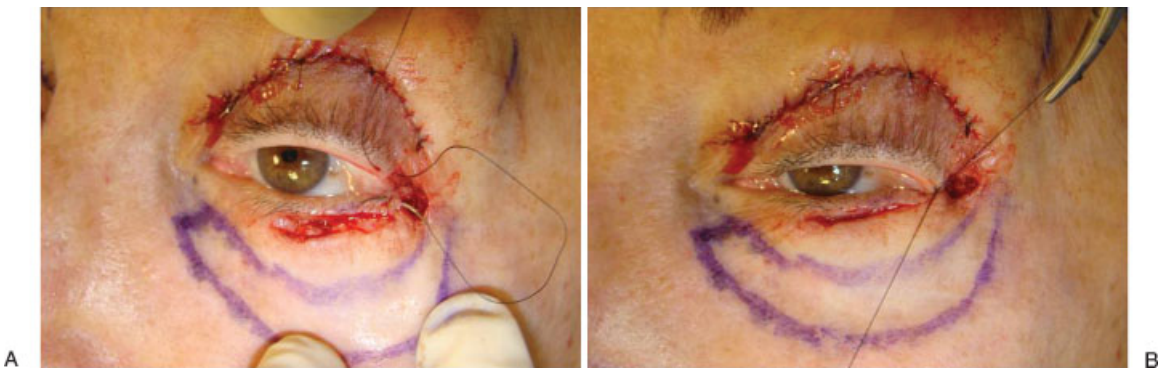
In patients for whom I believe there is a higher risk of lower lid retraction (prominent eye, skin excision in borderline patient, reoperation, etc.), I often add an intermarginal suture. I secure the temporal upper and lower lid with a 5-0 chromic suture placed through a few millimeters of skin and muscle and exiting and entering the gray line of the upper and lower lid (Fig. 14). In doing this, when the patient opens the eyes in the postoperative period, the lower lid will be elevated in a tonic fashion at the canthus. This provides another layer of support for the lower lid and further aids in preventing lower lid retraction. On occasion, a patient may feel claustrophobic from this, and I release the suture after surgery.

### Skin Excision

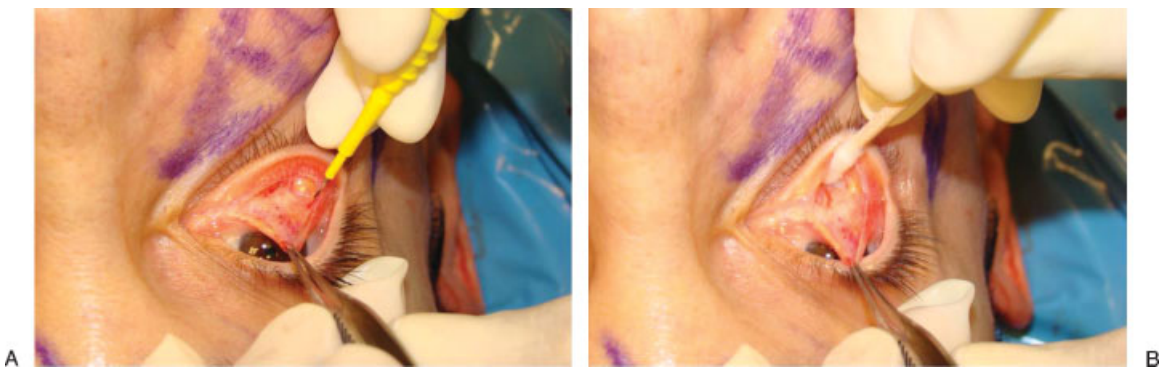
I excise lower eyelid skin through a subciliary skin flap only. I am generally conservative in the amount of skin excised. When the orbicularis muscle is suspended laterally, more skin can be recruited for excision. Finally,



**Figure 11** Canthoplasty procedure. Note (A) canthotomy, (B) identification of terminal tarsus, (C) engaging tarsus with suture, and (D) securing tarsus to periosteum.

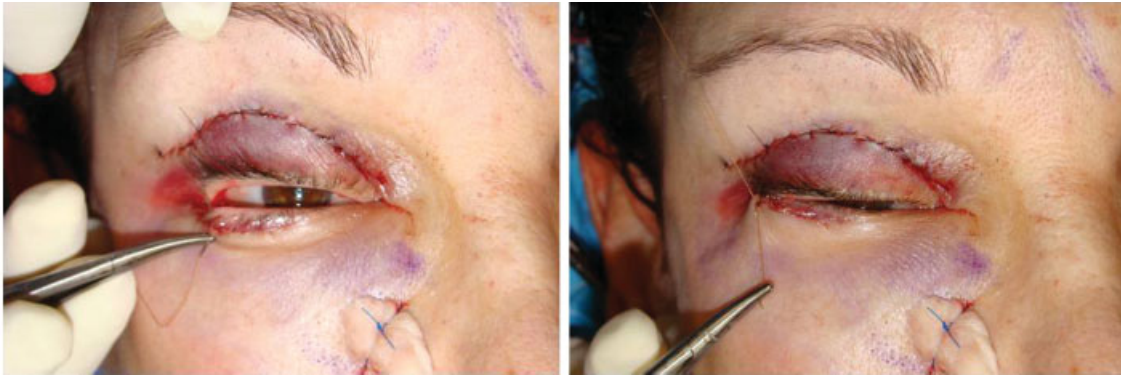

**Figure 12** (A) Canthal alignment suture passing from gray line of the upper lid to gray line of the lower lid. (B) The suture secured with good canthal alignment.



**Figure 13** (A) Transconjunctival incision, with (B) release of retractors with blunt dissection in postorbicular fascial plane.





**Figure 14** Temporary intermarginal suture. Chromic suture (A) passed through temporal lower lid and (B) tied after passage through upper lid.

when fat is grafted to the lower lid (tear trough), I compensate with slightly less skin excision as the volume change inflates preexisting skin.

## FAT GRAFTING

### Fat Harvesting

There are many appropriate donor sites for harvesting fat for injection. I focus on the lower abdomen and inner thighs because of surgical simplicity. Most surgeons perform periocular fat grafting in association with more involved eyelid and associated surgery (brow-lift, blepharoplasty, midface surgery). In these instances, many patients are consciously sedated or under general anesthesia. Harvesting fat in this scenario is easiest with the patient in the supine position (no need to reposition the patient).

If the procedure is performed under general anesthesia, the donor site is anesthetized with 0.25% Xylocaine with 1:400,000 epinephrine (a mix of 10 mL 1% Xylocaine and 1:100,000 epinephrine with 30 mL saline). If the procedure is performed under conscious sedation anesthesia, the concentration of injectable Xylocaine is increased (for better pain control) to 0.5% Xylocaine with 1:200,000 epinephrine (a 50/50 mix of Xylocaine 1:100,000 epi and saline).

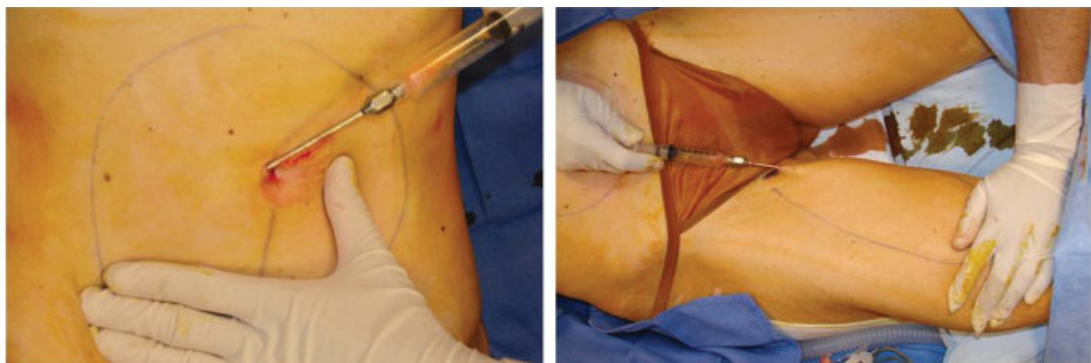
For the lower abdomen, the skin is entered within the umbilicus, and for the inner thigh it is entered at the inguinal line. The entry site of the skin is injected with a wheal of 1% Xylocaine with 1:100,000 epinephrine. The skin is penetrated with a scalpel blade. The appropriate dilute anesthetic is injected with a long 22-gauge spinal needle in a fan-like manner superficially and then deeper.

The fat is harvested with a nontraumatic canula (2 mm) engaged to a 10-cc syringe with minimal manual suction. This leads to the least trauma to fat. The fat is harvested at middle depth in a fan-like process similar to how anesthetic is injected.

In the abdomen, fat is harvested from both lower lateral quadrants of the abdomen. An attempt should be made to avoid fat harvesting from the lower midline, unless necessary, as it is more fibrous and sensitive (if under conscious sedation).

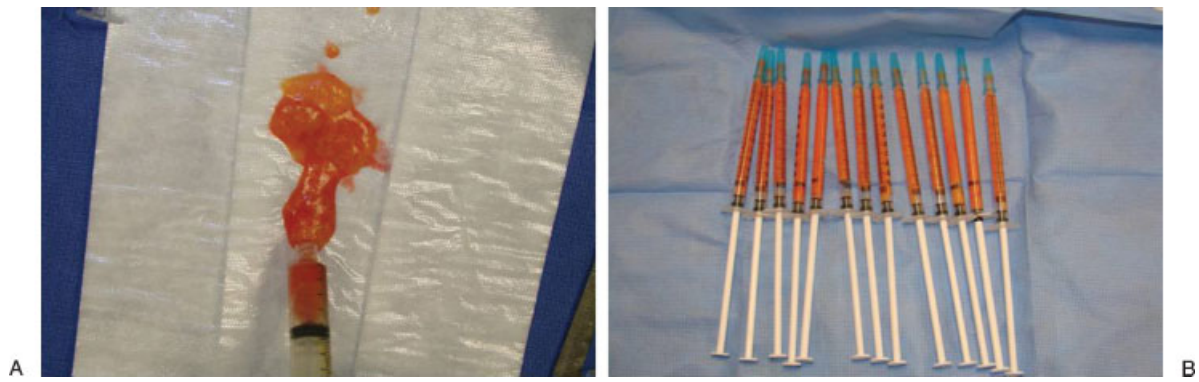
In the inner thigh, a fascial layer is “popped” through as the skin is entered, and fat is harvested in a fan-like manner. The fanning and harvesting at middle depth is preferred to avoid contour defects (although rare). The donor entry site is closed with 6-0 plain gut suture, and a Steri-Strip (3M Healthcare, St. Paul, MN) can be applied for dressing (Fig. 15).

The fat is emptied onto Telfa (Kendall Healthcare Products, Mansfield, MA) and all fluid is allowed to



**Figure 15** Fat harvesting donor sites: (A) periumbilical; (B) inner thigh.





**Figure 16** I do not process or store the harvested fat. If one chooses these techniques, there are several articles and book chapters that cover these methods.

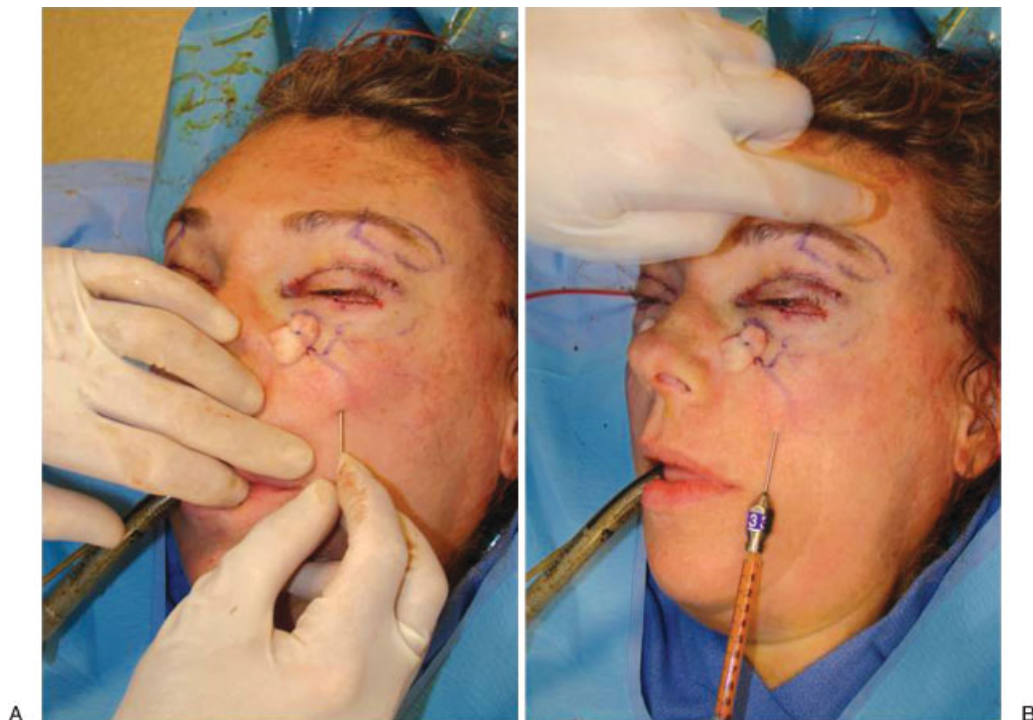drain off the fat. The fat is then placed into another 10-cc syringe with a tongue depressor and directly transferred into 1-cc syringes (Fig. 16). The fat is injected (grafted) with 1-cc syringes to avoid excess pressure when injecting the fat (less cell damage) and to avoid inadvertent injection of larger deposits of fat (which could decrease survival and increase irregularities).

### Fat Injections

Prior to surgery, the areas for grafting fat are predetermined and demarcated. The fat injection entry sites for the periocular area are on the cheek, temporal to the lateral canthus, and on the forehead above the brow.

If the patient is awake, regional blocks are given to the infraorbital, zygomatico-temporal, zygomatico-facial, lacrimal, and supraorbital neuro-bundles. In addition, a wheal of anesthesia is given to the cannula entry sites. The local anesthetic is augmented as needed for pain control, paying special attention to avoiding swelling and distortion from anesthetic injection.

The facial skin is entered with an 18-gauge needle. The fat is injected with multiple passes in varied tissue planes and depths (Fig. 17). The deeper injections are for volume augmentation and are more forgiving in terms of surface irregularities. When injecting in superficial planes, care must be taken to avoid contour deformities (lumps and bumps). I suggest advancing to



**Figure 17** Fat grafting technique: (A) entry with 18-gauge needle; (B) injection.

superficial injections as one gains experience with the technique and outcomes. The grafting entry sites can be allowed to heal by secondary intent.

## COMPLICATIONS OF SURGERY

The most common complications of surgery are excess or persistent bruising and swelling. This is more frequent when fat is repositioned, grafted, or when canthal surgery is added. In these instances, I routinely prescribe a low-dose steroid taper after surgery ([Medrol Dose Pack] Methylprednisolone, Pfizer Inc., Irvine, CA) and reassure the patient.

I see chemosis is less than 10% of cases. Chemosis occurs most frequently when the transconjunctival incision is too low and when the canthus is violated. In both instances, the lymphatic outflow is altered. I treat chemosis with oral and topical steroids, which is usually enough. In rare instances, pressure patch, temporary tarsorrhaphy, or conjunctival cut down (refractory cases) is needed.

I see subconjunctival hemorrhage in less than 3% of cases. This occurs as blood enters the subconjunctival space. This is a self-limiting problem that resolves over 7 to 14 days but unfortunately frightens patients.

In straight fat excision blepharoplasty, undercorrection (residual fat) is most common temporally and requires re-excision, which is straightforward. Conversely, overcorrection (sunken orbit) can be difficult to correct and requires filling (dermis fat, injected fat or synthetic filter).

When fat is repositioned, granulomas of the preserved fat can occur. These usually resolve with mechanical massage and steroid injections. On rare occasion, excision is required.

Diplopia can occur as a transient phenomenon after surgery with or without repositioning fat. This is most commonly related to anesthesia (local infiltration) effect or trauma to the inferior oblique muscle. When related to anesthesia, the problem resolves spontaneously over the first 24 hours. The patient rarely complains as he or she is somewhat blurred after surgery. When it is related to muscle injury, oral steroids usually speed recovery. On rare occasion, with overt muscle trauma, muscle surgery may be needed.

Fat grafting has its own set of unique potential problems, such as prolonged edema, contour irregularities (lumps/bumps), and bulges (more coalesced prominences). It is important to differentiate prolonged edema from overcorrection of injected fat (which I call a bulge). In cases of edema, the prominence is more evident in the morning, creates a ledge at the lid/cheek junction, and can be compressed with creation of a depression (from displaced fluid). This will resolve over time (can be months) with massage, oral and/or injectable steroids, reducing salt intake,

elevating the head of the bed, pressure taping, and so forth.

Conversely, overcorrection of fat presents with a more stable appearance. Fat overcorrection can be treated with microliposuction (which I find somewhat tedious) or surgical excision. The excision can be transcutaneous with a subciliary incision and skin flap until the fat is identified or with direct incision above the prominence. A scar can develop but heals well especially if in the nasal trough.

The excision can also be performed through a transconjunctival incision. If the excision is performed through a transconjunctival incision, the surgeon needs to realize that the fat is usually not in its native location (retroseptal). It is often located preseptal and within the muscle. I typically use my finger to push the fat under the eyelid retractor and buttonhole the muscle until the fat prolapses.

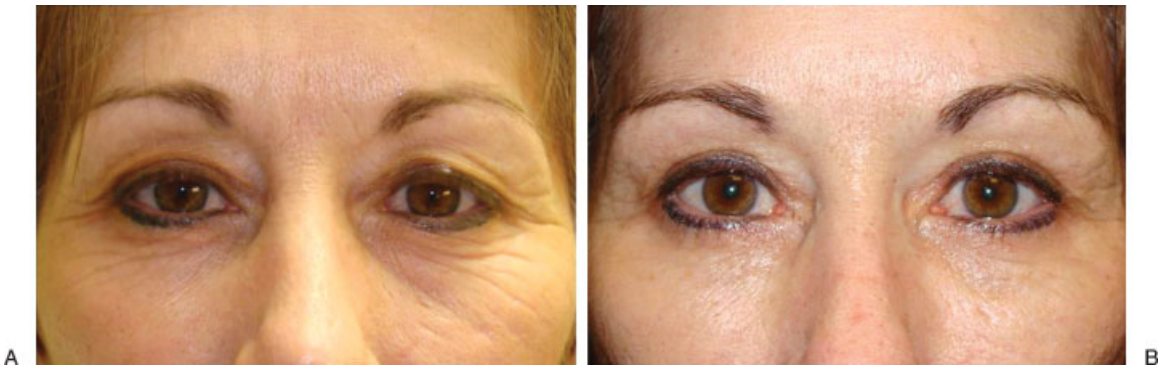Contour irregularities (lumps and bumps) are usually smaller indurations (nodules) of fat. In my experience, these are more common than bulges. Contour irregularities can be treated with steroid injections or, if this fails, excision as described above. The best way to avoid these irregularities is with a proper injection technique. Proper injection technique involves injections of small aliquots of fat (reduce antigen load) at multiple levels. Injecting the fat at deeper planes reduces the risk of contour irregularities substantially.

Undercorrection can occur and will require re-injection at a later date. I now wait at least a year to reinject as there have been instances where areas that appear undercorrected enlarge over time.

Complications of canthal surgery include the prolonged bruising and swelling mentioned above, canthal nodules, abscesses, and malposition. Canthal nodules, or indurations, are typically inflammatory and resolve with time. They can be palpable, painful, and a nuisance. I occasionally inject them with steroid if the patient is bothered. A suture abscess can occur, which requires oral antibiotics and in-office drainage. Canthal malposition is rare and usually resolves at the 2-month period after surgery, as things settle. Maintaining the integrity of the inferior crus of the lateral canthal tendon and avoidance of lid shortening help avoid canthal malposition. A slanted lower lid (cat-eye appearance) is also uncommon but can appear after a few months and is avoidable with the techniques described above.

## THOUGHT PROCESS: PATIENT EXAMPLES

To exemplify the various procedures described and their utility in lower eyelid rejuvenation, I have selected three examples that span the spectrum of patient presentations and how I manage these cases using the SMFTV system for analysis.



**Figure 18** Case 1. (A) Preoperative and (B) postoperative views of a patient who underwent skin excision, canthoplasty, orbicularis plication, nasal trough fat grafting, retractor lysis, intermarginal suture (preventative), and postoperative subciliary Botox (4 U each side). She also had upper blepharoplasty.

### Case 1 (Vector Neutral Lid without Fat Prominence but with Excess Skin)

A 48-year-old woman presents with complaints of excess lower lid skin, rhytides, and slight hollowness. It is important for her to have surgery without altering the shape of her eyes. Using the SMFTV method, her examination reveals mild excess skin, a moderate degree of eyelid laxity and decreased muscle tone, no excess fat, and a vector neutral lid with a mild tear trough deformity. Her surgery consisted of bilateral skin flap with conservative skin excision, muscle strap (canthopexy), canthoplasty (tarsus secured), retractor lysis, intermarginal suture, minimal fat grafting to the tear trough, and postoperative lower eyelid Botox (onabotulinumtoxin A, Allergan Pharm, Irvine, CA) (after one month). Note her postoperative result and the comparison to her preoperative appearance (Fig. 18).

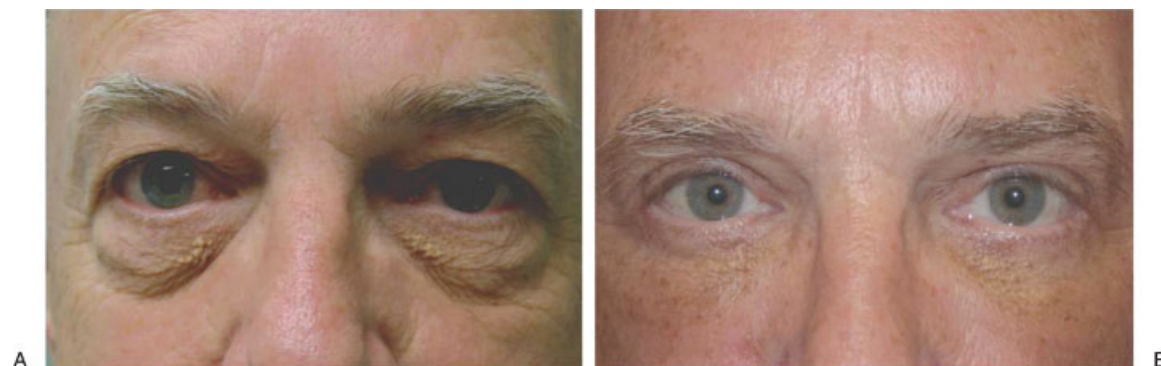In this case, lid tightening and skin excision was low risk as the lid was vector neutral. The retractor lysis and intermarginal suture were added to swing the equilibrium of lid position to “elevation” postoperatively. A small amount of fat was grafted to the nasal tear trough for volume.

### Case 2 (Vector Neutral Lid with Excess Fat Prominence and Excess Skin)

This 62-year-old man had concerns over looking tired with lower eyelid “bags.” He put no limitations on what surgery to undergo. The SMFTV method revealed excess skin, both eyelid and muscle laxity, herniated lower lid fat, and a vector neutral lid with significant tear trough. He also had severe xanthelasma.

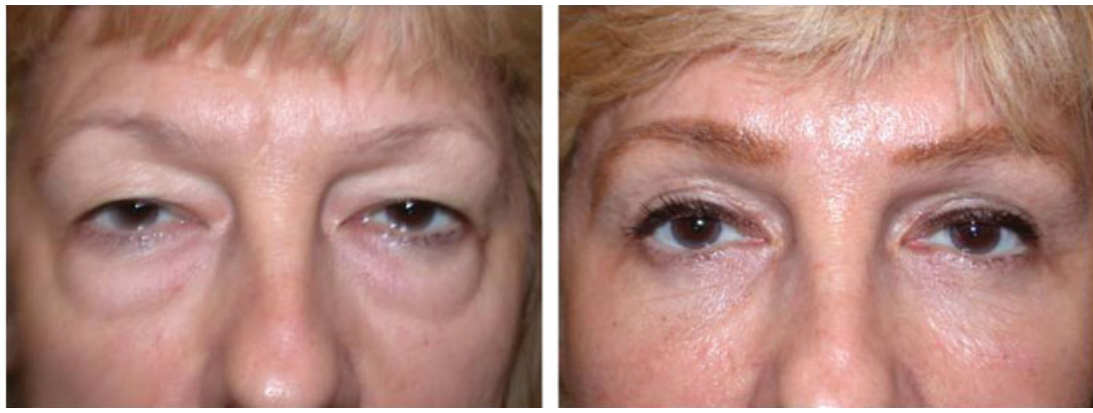He underwent transconjunctival lower lid blepharoplasty with skin excision and muscle strapping. He also had a true canthoplasty. The tear trough was effaced with nasal fat repositioning and central/temporal fat grafting. An intermarginal suture was placed for 4 days. It was decided to address the xanthelasma at a later date as not to overly complicate the procedure.

This gentleman received the full gamete of procedures. As he has a vector neutral lid, lid tightening and skin excision did not overtly increase the risk of lower lid malposition. He is an example of how nasal fat repositioning and central/temporal trough fat grafting work well together. His postoperative result is depicted in Fig. 19.

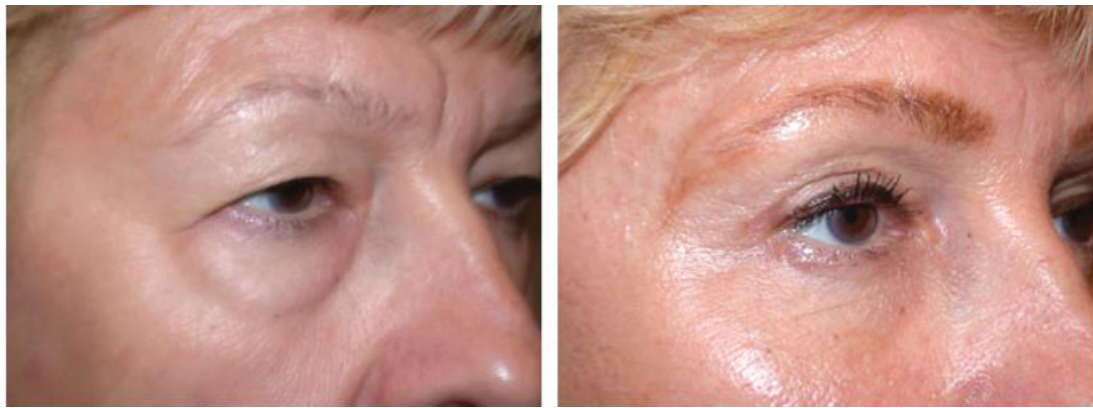

**Figure 19** Case 2. (A) Before and (B) after photographs of man who underwent skin excision, transconjunctival blepharoplasty with nasal trough fat repositioning, central/temporal fat grafting, canthoplasty, orbicularis plication, and intermarginal suture for support. He also had upper blepharoplasty. His xanthelasma will be addressed in a staged procedure.





**Figure 20** Case 3. As opposed to the previously noted two patients, this woman presented with a negative vector. She underwent lower lid transconjunctival blepharoplasty with nasal fat repositioning, central/temporal fat grafting, and conservative canthopexy. She also had temporal brow stabilization and upper blepharoplasty. Note her results: (A) before surgery; (B) after surgery.



**Figure 21** (A) Preoperative and (B) postoperative side views of patient in Fig. 20. Note how vector improves postoperatively with fat grafting.

**Case 3 (Negative Vector Lid with Excess Fat Prominence but no Excess Skin)**

A 60-year-old woman presented with “bags and dark circles.” She desired a youthful and natural look. Her examination revealed a negative vector eyelid, borderline lid tone (minimal laxity), no excess skin, and significant tear trough deformity. She underwent transconjunctival lower lid blepharoplasty, nasal fat repositioning, central/temporal fat grafting, and muscle strap (canthopexy). She was very pleased with the postoperative outcome (Figs. 20 and 21).

In this woman’s case, the negative vector predisposed her to lower lid malposition if skin were to be excised or if the lid was overly tightened. Thus, care was taken with conservative canthopexy only.

**CONCLUSION**

The preceding examples depict patient presentations that represent the various factors that must be addressed

to properly aesthetically rejuvenate a lower eyelid. The goals of surgery are to re-create eyelid support in the manner described without creating undue risk of eyelid malposition.

Identifying the various deficiencies present with regard to skin, muscle, and eyelid tone are critical for surgical success. Including the more contemporary concepts of volume preservation/augmentation, vector identification (SMFTV method) and preservation of the integrity of the orbital septum and orbicularis muscle (bilamellar surgery) into the surgical plan greatly assists in attaining this outcome.

**REFERENCES**

1. Neuhaus R, Baylis H. Complications of lower eyelid blepharoplasty. In: Putterman AM, ed. *Cosmetic Oculoplastic Surgery*. New York, NY: Grund Stratton; 1982
2. McGraw BL, Adamson PA. Postblepharoplasty ectropion. Prevention and management. *Arch Otolaryngol Head Neck Surg* 1991;117:852–856

3. Taban M, Douglas R, Li T, et al. Efficacy of "thick" acellular human dermis (allograft) for lower eyelid retraction. *Arch Facial Plast Surg* 2005;7:38–44
4. Reidy JP. Swellings of eyelids. *Br J Plast Surg* 1960;13:256–267
5. Marshak H, Dresner S. Transconjunctival lower blepharoplasty. In: Azizzadeh B, Murphy M, Johnson C, eds. *Master Techniques in Facial Rejuvenation*. Philadelphia, PA: Saunders Elsevier; 2007:89–98
6. Fagien S. Algorithm for canthoplasty: the lateral reticular suspension: a simplified suture canthopexy. *Plast Reconstr Surg* 1999;103:2042–2053; discussion 2054–2058
7. Knize DM. The superficial lateral canthal tendon: anatomic study and clinical application to lateral canthopexy. *Plast Reconstr Surg* 2002;109:1149–1157; discussion 1158–1163
8. Schiller JD, Bosniak S. Blepharoplasty: conventional and incisional laser techniques. In: Mauriello, JA, eds. *Unfavorable Results of Eyelid and Lacrimal Surgery*. Boston, MA: Butterworth-Heinemann; 2000:3–10
9. Baylis HI, Long JA, Groth MJ. Transconjunctival lower eyelid blepharoplasty. Technique and complications. *Ophthalmology* 1989;96:1027–1032
10. Mullins JB, Holds JB, Branham GH, Thomas JR. Complications of the transconjunctival approach. A review of 400 cases. *Arch Otolaryngol Head Neck Surg* 1997;123:385–388
11. Hamra ST. The role of orbital fat preservation in facial aesthetic surgery. A new concept. *Clin Plast Surg* 1996;23:17–28
12. Nassif PS. Lower blepharoplasty: transconjunctival fat repositioning. *Facial Plast Surg Clin North Am* 2005;13:553–559, vi
13. Goldberg RA. Transconjunctival orbital fat repositioning: transposition of orbital fat pedicles into a subperiosteal pocket. *Plast Reconstr Surg* 2000;105:743–748; discussion 749–751
14. Hamra ST. The role of the septal reset in creating a youthful eyelid-cheek complex in facial rejuvenation. *Plast Reconstr Surg* 2004;113:2124–2141; discussion 2142–2144
15. Coleman SR. Structural lipoaugmentation. In: Narins RS, ed. *Safe Liposuction and Fat Transfer*. New York, NY: Marcel Dekker; 2003:409–423
16. Lam SM, Glasgold MJ, Glasgold RA. Complimentary fat grafting. Chapter 1: Aesthetic and aging: a new paradigm. First edition. Philadelphia, PA: Lippincott Williams & Wilkins; 2007:1–11
17. Massry GG. Transconjunctival approach to lower-lid blepharoplasty. In: Shiffman MA, Mirrafati SJ, Lam SM, eds. *Simplified Facial Rejuvenation*. New York, NY: Springer; 2008:471–474
18. Anderson RL, Gordy DD. The tarsal strip procedure. *Arch Ophthalmol* 1979;97:2192–2196